

Saphenous Vein Pseudoaneurysm Associated with Cardiac Catheterization in a Patient with Femoro-popliteal By Pass using by Saphenous Vein

***Oruc Alper Onk, **Eyup Serhat Calik, *Bilgehan Erkut**

*Erzincan University Medical Faculty, Training and Research Hospital, Cardiovascular Surgery Department, Erzincan, Turkey

**Erzurum Regional Training and Research Hospital, Cardiovascular Surgery Department, Erzurum, Turkey

Correspondence: Bilgehan Erkut, Prof, MD.
Erzincan University Medical Faculty,
Training and Research Hospital,
Cardiovascular Surgery Department,
Erzincan, Turkey

Phone: 0090 442 232 6161, E-mail: bilgehanerkut@yahoo.com

The common femoral artery is commonly used as arterial access for a wide range of radiological and cardiological procedures. Femoral pseudoaneurysm (FPA) is one of the common complications of percutaneous catheterization procedures performed via the femoral artery. We present a case of a patient developed a false aneurysm that performed peripheric arterial bypass graft before.

A 69-years-old man, who had progressive swelling and pain at right hip, was admitted to our clinic. In his history, there were aorta-femoral graft bypass with synthetic graft and right femoro-popliteal bypass graft with saphenous vein operations, 2 years ago. The patient was made coronary angiography from right inguinal site for chest pain, 10 days ago. After angiography, the swelling occurred to the right femoral region. For diagnose, we were used arterial Doppler ultrasonography and magnetic resonance imaging angiography (Fig.1). In radiological techniques, the pseudoaneurysm was determined in right femoral site. Operation was made by general anesthesia. We seen pseudoaneurysm sac approximately in size 76 x 55 mm next to proximal of ileo-femoral

junction in operation (Fig.2). After the femoral artery was controlled from distal and proximally, we made a direct incision to the aneurysmatic sac. The pseudoaneurysm was arising from end-to-side anastomosis of the saphenous vein of the femoro-popliteal bypass graft. After sac excise, patch-plasty was performed to this lesion by using synthetic graft for arterial defect and then the femoro-popliteal bypass grafting was refreshed by using sapheneus vein. Postoperative all pulses were palpable. The patient was discharged without complication at sixth day.

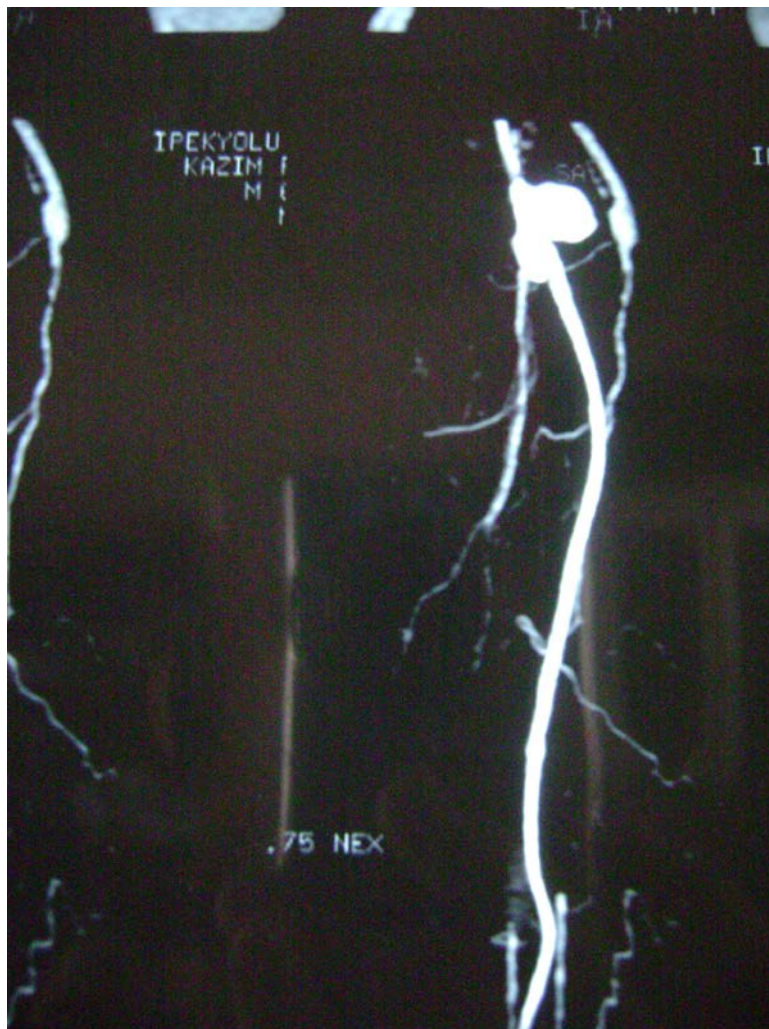

Fig. 1: The pseudoaneurysm was determined in magnetic resonance imaging angiography.

Due to the development of technology and experience, more and more diagnostic and interventional catheterization procedures are performed workaday. Pseudoaneurysm is a common complication in patients undergoing diagnostic or therapeutic catheterization. If the patient was operated with autogenous or non-autogenous graft for a lesion of lower extremities, using of upper extremity arteries for preventing complications of invasive arterial procedures is more convenient and safety.

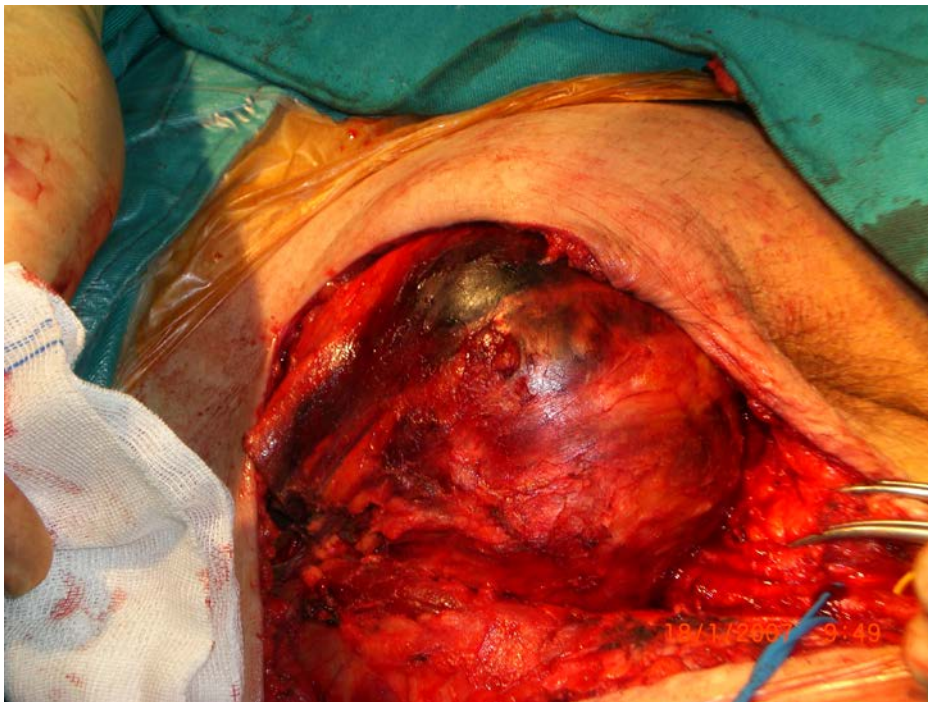


Fig. 2: Peroperatively, pseudoaneurysm sac was seen femoral site.

Key words: Cardiac catheterization, pseudoaneurysm, complication, surgery

{**Citation:** Oruc Alper Onk, Eyup Serhat Calik, Bilgehan Erkut. Saphenous vein pseudoaneurysm associated with cardiac catheterization in a patient with femoro-popliteal by pass using by saphenous vein. American Journal of Research Communication, 2015, 3(5): 28-30} www.usa-journals.com, ISSN: 2325-4076.